

## CASE REPORT

# Invasive Mole Presenting as Ectopic Pregnancy: A Rare and Life-Threatening Case

Akansha Goel<sup>1</sup>, Juhi Deshpande<sup>2</sup>, Shantanu Mishra<sup>3</sup>**How to cite this article:**

Akansha Goel, Juhi Deshpande et al. Invasive Mole Presenting as Ectopic Pregnancy: A Rare and Life-Threatening Case. Indian J Obstet Gynecol. 2025; 13(2): 69-73.

**ABSTRACT**

We report a rare case of invasive mole causing uterine rupture and massive hemoperitoneum, masquerading as ectopic pregnancy. A 22-year-old woman presented with severe abdominal pain and shock at 6 weeks gestation. Imaging suggested ectopic pregnancy, but laparotomy revealed 2000cc of hemoperitoneum and a perforated uterus with grape-like vesicles and active bleeding. Despite evacuation and devascularization, bleeding persisted, necessitating a life-saving total abdominal hysterectomy.

**KEYWORDS**

• Ectopic pregnancy • Hemoperitoneum • Invasive mole

**INTRODUCTION**

Invasive mole, or chorioadenoma destruens, accounts for 15% of all gestational trophoblastic neoplasia (GTN) cases.<sup>1</sup> GTN is characterized by abnormal chorionic villi, villous stroma edema, and varying trophoblastic proliferation.<sup>1</sup> The presence or absence of fetal elements distinguishes complete from partial moles.<sup>2</sup> If molar pregnancies fail to regress, they can

progress to invasive mole, choriocarcinoma, persistent trophoblastic tumor, or placental site trophoblastic tumor.<sup>2</sup>

Molar pregnancies can progress to invasive moles in 20% of cases, more commonly in complete molar pregnancies.<sup>3,4</sup> Chorioadenoma destruens, a trophoblastic tumor, invades the myometrium through direct extension or venous channels,

**AUTHOR'S AFFILIATION:**

<sup>1</sup> Assistant Professor, Department of Obstetrics and Gynecology, Government Medical College, Jalaun, Uttar Pradesh, India.

<sup>2</sup> Associate Professor, Department of Obstetrics and Gynecology, Baba Kinaram Autonomous State Medical College, Chandauli, Uttar Pradesh, India.

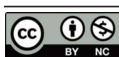<sup>3</sup> Assistant Professor, Department of Surgery, Government Medical College, Jalaun, Uttar Pradesh, India.

**CORRESPONDING AUTHOR:**

**Juhi Deshpande**, Associate Professor, Department of Obstetrics and Gynecology, Baba Kinaram Autonomous State Medical College, Chandauli, Uttar Pradesh, India.

E-mail: juhidesh@yahoo.com

➤ **Received:** 31.03.2025 ➤ **Accepted:** 30.04.2025



Creative Commons Non Commercial CC BY-NC: This article is distributed under the terms of the Creative Commons Attribution NonCommercial 4.0 License (<http://www.creativecommons.org/licenses/by-nc/4.0/>) which permits non-Commercial use, reproduction and distribution of the work without further permission provided the original work is attributed as specified on the Red Flower Publication and Open Access pages (<https://www.rfppl.co.in>)

characterized by persistent edematous chorionic villi and trophoblastic proliferation.<sup>5</sup> The presence of villi distinguishes invasive mole from choriocarcinoma. Uncommonly, chorioadenoma destruens presents as ruptured ectopic pregnancy, incomplete abortion, menorrhagia, or endometrial carcinoma, rather than vaginal bleeding.<sup>6,7</sup> We report a rare case of invasive mole causing uterine rupture, massive hemoperitoneum, and shock, mimicking ectopic pregnancy.

## CASE

A 22-year-old primigravida presented to the emergency room with sudden, severe lower abdominal pain that began one hour prior. The pain was colicky, radiating to her back and thighs, but she reported no nausea, vomiting, or fever. Her medical and surgical histories were unremarkable, with no known allergies or current medications. She had regular menstrual cycles since menarche at age 12 and denied previous pregnancies, with a one-year

married life.

On examination, the patient was awake, alert, and oriented, but appeared distressed. Her vital signs revealed hypotension (BP 90/60 mmHg), tachycardia (112 bpm), and pallor. She was afebrile, with a respiratory rate of 16/min. Cardiac, respiratory, and neurological system evaluations were unremarkable.

Abdominal examination revealed severe tenderness in the bilateral lower quadrants, accompanied by guarding, rigidity, and rebound tenderness. Bimanual examination showed a closed cervical os, but the uterine size could not be assessed due to guarding and tenderness. These findings suggested ectopic pregnancy, prompting an emergency transvaginal ultrasound (TVS) (Figure 1) The TVS revealed an anteverted uterus (46 x 60 x 76 mm) with irregular echogenic products in the uterine cavity and moderate free fluid in the pouch of Douglas. However, a definitive diagnosis of ectopic pregnancy could not be confirmed.

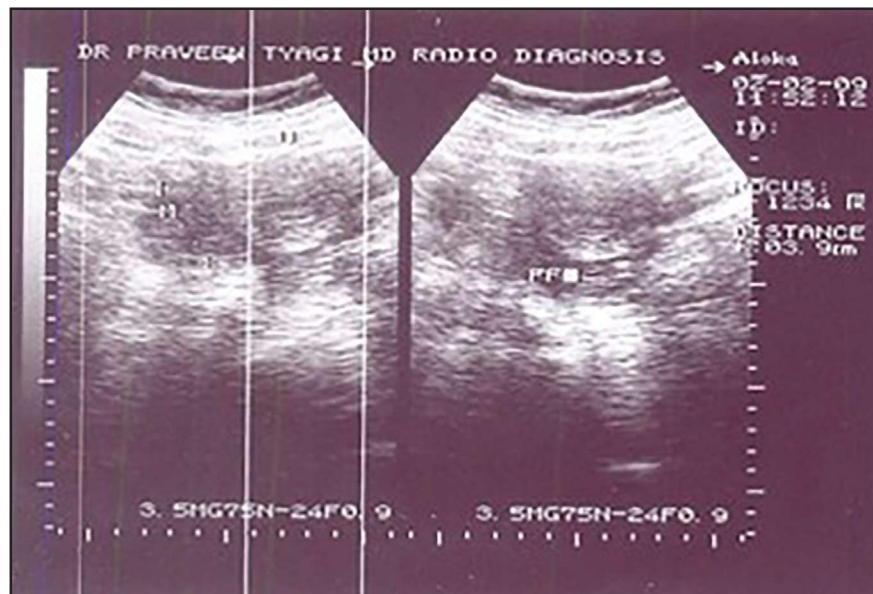


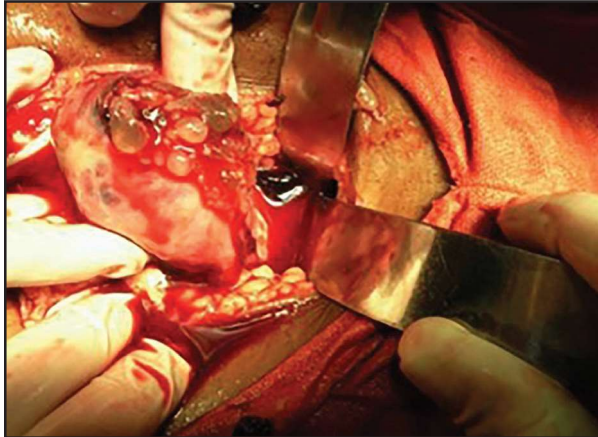
Figure 1: TVS before surgery

During the TVS, the patient's condition rapidly deteriorated, becoming drowsy and slipping into a semi-comatose state. Her vital signs worsened, with a pulse of 144/min and systolic blood pressure of 70 mmHg. She was immediately rushed to the operation theatre for emergency laparotomy, with a suspected diagnosis of ruptured ectopic pregnancy. Preoperative laboratory investigations revealed severe anemia (Hb 6.5g/dL, Hct

22%), normal renal function (Serum creatinine 0.89mg/dL), and mildly elevated random blood sugar (130mg/dL). Beta HCG sample was sent for examination.

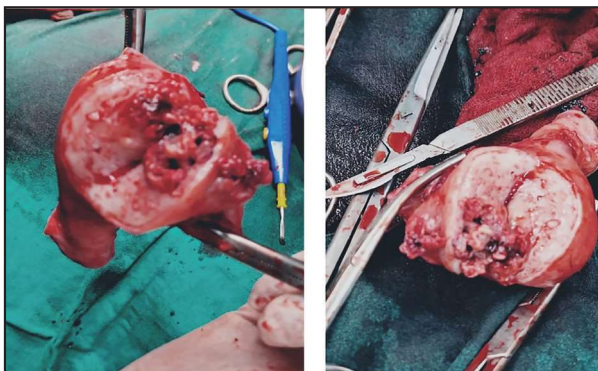Exploratory laparotomy revealed a massive hemoperitoneum of 2000cc, with the peritoneal cavity filled with blood and clots. A perforation was noted at the uterine fundus, with active bleeding at the site. Grape-like vesicles,

measuring 3cm x 3cm, protruded through the perforation (Figure 2). The uterus was enlarged to approximately 8 weeks' size, soft, and bulky. Bilateral adnexae appeared normal, and no ectopic or metastatic tissue was identified on further abdominal exploration.



**Figure 2:** Uterine rupture at the fundus, revealing grape-like vesicles and significant hemorrhage

Despite complete uterine evacuation, profuse bleeding persisted from the perforation site, and the patient remained in shock, unresponsive to fluid replacement, 4 units of blood transfusion, and continuous oxytocin infusion. Stepwise uterine devascularization was attempted with help of consultant of Surgery Department, to achieve hemostasis, but bleeding continued unabated. As a life-saving measure, a total abdominal hysterectomy was performed, after which the patient became hemodynamically stable. The resected uterus was sent for histopathological examination (Figure 3, Figure 4).

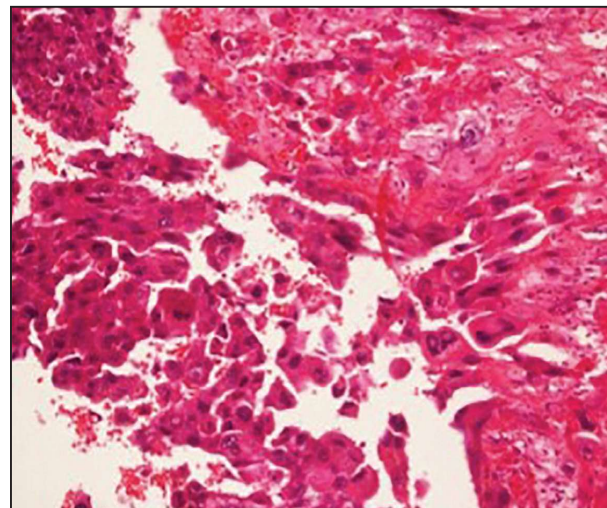


**Figure 3, 4:** Uterus following hysterectomy showing chorioadenoma destruens with tissue

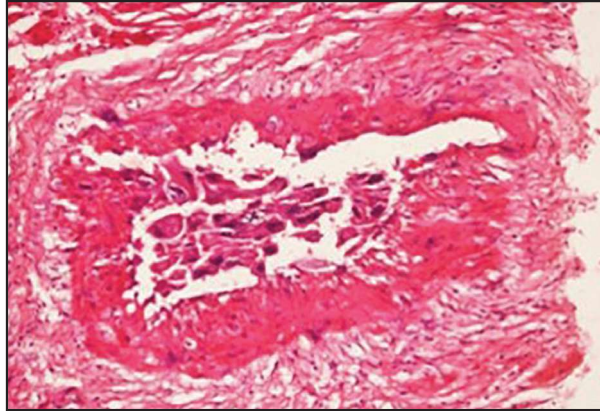
The patient's postoperative course was uneventful. By postoperative day one, her vital signs had improved, and her hemoglobin

level was 8g/dL. She received an additional two units of blood transfusion, facilitating a smooth recovery. A postoperative metastatic workup, including serum biochemistry, chest x-ray, and upper abdominal ultrasonography, revealed no evidence of metastasis. Due to low serum  $\beta$ -hCG levels, the patient was monitored with serial quantitative  $\beta$ -hCG estimations to consider chemotherapy if levels plateaued or rose. The initial postoperative  $\beta$ -hCG level was 120mIU/mL. She was discharged in stable condition on postoperative day three. Two weeks post-surgery, her  $\beta$ -hCG level had dropped to <6mIU/mL, and subsequent levels remained negative during regular follow-up visits.

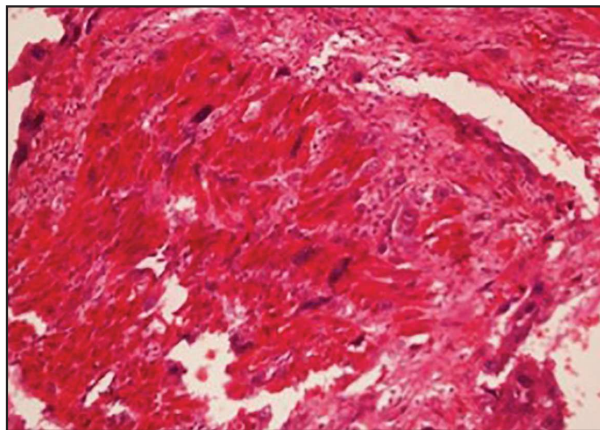
Further questioning revealed a history of evacuation for incomplete abortion approximately two months prior, although records were unavailable for review. It remained unclear whether this presentation was a continuation of the previous conception or a new pregnancy. Histopathological examination confirmed Chorioadenoma Destruens with myometrial and blood vessel invasion. Microscopic examination of the endomyometrium revealed trophoblastic cells with abundant eosinophilic cytoplasm and pleomorphic nuclei invading deep into the myometrium, reaching the serosal layer in some areas. Additionally, trophoblastic cells were seen invading blood vessels, which likely contributed to the patient's severe bleeding. (Figure 5, Figure 6, Figure 7)



**Figure 5:** Section from uterus showing a tumour arising from endometrial surface and composed of intermediate trophoblasts and a few multinucleated syncytiotrophoblasts, arranged in sheets. (H&E, X40)



**Figure 6:** The tumour cells are showing vascular invasion. (H&E, X 20)



**Figure 7:** Syncytiotrophoblasts and intermediate trophoblasts are infiltrating the myometrium as single cell infiltrate. (H&E, X 20)

## DISCUSSION

Gestational trophoblastic neoplasms (GTN) encompass a range of proliferative and degenerative disorders affecting placental tissue, comprising complete or partial mole (90%), invasive mole (5-8%), choriocarcinoma (1-2%), and placental site tumor (1-2%). Approximately 15% of complete moles progress to invasive mole, whereas only 2-4% of partial moles undergo this transformation<sup>8</sup>.

Complete hydatidiform moles possess a potential for uterine invasion or distant metastasis. Invasive moles can perforate the myometrium, causing uterine perforation and intraperitoneal bleeding.<sup>9</sup> Although direct vascular invasion and metastasis are rare in invasive moles, the lung is the most commonly reported site, and despite being generally less malignant than choriocarcinoma,<sup>10</sup> invasive moles can still be associated with fatal metastasis. Myometrial trophoblastic invasion

likely occurs to some extent in most moles, and this phenomenon is not unique to molar pregnancies. Hertig and Borrowing employed terminology from myometrial placentation to classify invasive moles into accreta, increta, and percreta.<sup>11</sup> Uterine rupture in gestational trophoblastic neoplasia often has catastrophic consequences due to massive bleeding, which can be potentially lethal.

Management of invasive mole often involves hysterectomy, but in reproductive-age patients, uterine resection of localized disease may be performed, as reported by Mittal *et al.*<sup>7</sup> Diagnosis relies on demonstrating a complete hydatidiform mole invading the myometrium or presence of villi in metastatic lesions. However, myometrial invasion can be challenging to confirm via pelvic ultrasound or uterine curettings, unless sufficient myometrium is present. Transvaginal sonography combined with HCG titers offers a non-invasive diagnostic approach<sup>8</sup>. Color flow Doppler can identify lesions with increased vascularity, characteristic of invasive disease. A study by Branka *et al.*<sup>12</sup> found that sonography failed to detect specific uterine changes even one month after GTN development, highlighting its limited value in detecting partial moles and malignant GTNs. Nevertheless, massive tissue destruction, hot spots (hypervascularization), and low resistance index are characteristic ultrasound findings of malignant GTNs. The role of magnetic resonance imaging and positron emission tomography in evaluating women with GTN remains undefined.<sup>7,8,12</sup>

Our experience highlights the importance of maintaining a high index of suspicion for gestational trophoblastic neoplasia in women with a history of abortion and irregular bleeding. Intra-operative management options are limited due to the acute presentation. Uterine evacuation is often the treatment of choice, but the use of oxytocin to achieve hemostasis is controversial. Mitani *et al.*<sup>13</sup> recommend partial resection for young women with invasive moles complicated by internal hemorrhage, reporting successful outcomes in four out of five patients who subsequently delivered healthy babies via cesarean section. Goldstein *et al.*<sup>14</sup> employed local uterine resection combined with bilateral internal iliac artery ligation to achieve hemostasis and preserve fertility.<sup>13,14</sup>

Chemoprophylaxis may be beneficial for patients with high-risk complete moles, particularly when hormonal follow-up is inaccessible or unaffordable, and the risk of losing the patient to follow-up is high. Recommended post-molar follow-up includes:

- Serial serum  $\beta$ -hCG measurements every 1-2 weeks after evacuation until levels normalize
- hCG levels 2-4 weeks after the first normal level
- hCG surveillance every 1-2 months for 6 months after the first normal hCG level

Serial hCG monitoring can provide early detection of recurrence in women with disease in prolonged remission (>1 year), although rare cases of gestational trophoblastic tumor (GTT) may be associated with undetectable hCG levels<sup>8</sup>.

In our patient, we were unable to achieve adequate hemostasis through stepwise uterine devascularization, including uterine and ovarian vessel ligation. A total abdominal hysterectomy was performed to save the life of the patient. Although chemotherapy has improved survival rates for gestational trophoblastic tumor patients, hysterectomy remains a crucial adjunct treatment for select patients. The use of chemotherapy in managing invasive mole is still debated, given the evidence of spontaneous regression of metastatic mole. Chemoprophylaxis may be beneficial for patients with high-risk complete moles, particularly when hormonal follow-up is inaccessible or unaffordable, and the risk of losing the patient to follow-up is high. In our case, chemotherapy was not considered due to the absence of metastasis and low  $\beta$ -hCG levels on subsequent follow-up. Although there was a risk of the patient being lost to follow-up, fortunately, this did not occur.

## CONCLUSION

Chorioadenoma destruens poses a significant risk of myometrial and vascular invasion, potentially leading to uterine perforation and catastrophic hemorrhage. To mitigate these risks, early first-trimester ultrasound is crucial for identifying such cases. Continued reporting and awareness of these cases are essential, enabling obstetricians to consider ruptured invasive mole as a differential diagnosis in young pregnant women presenting with acute onset lower abdominal pain.

## REFERENCES

1. Kumar S., Vimla N., Mittal S. Invasive mole presenting as acute hemoperitoneum. *JK science*. 2004; 6: 159-160.
2. Berkowitz R.S., Goldstein D.P., In: Berck JS. *Gestational trophoblastic neoplasm*. Philadelphia Lipincott, Williams and Wilkins, 2002.1353- 74.
3. D. Berek & Novak's *Gynecology*, 14th ed, Philadelphia, Lippincott Williams & Wilkins, 2007. pp. 1581-1604.
4. Kittur S., Venkatesh, Ramlingappa A. A rare case of invasive mole with silent uterine perforation. *Int J. Reprod Contracept Obstet Gynecol* 2013; 2: 109-10.
5. Atala C., Riedemann R., Biotti M., Ramírez F., Paublo M. Invasive mole with uterine rupture. *Rev Chil Obstet Ginecol*. 1992; 57(5): 356-8.
6. Singh A. and, Ratnani R.J. Heterogenous presentation of Chorioadenoma destruens. *J Obstet Gynaecol India*. Dec 2012; 62 (Suppl 1): 71-74.
7. Mandal D., Nandi N., Dey R.P., Biswas R.R., Bhattacharya A.K., Biswas S.C. Partial Invasive Molar Pregnancy - Two Case Reports. *Al Ameen J Med Sci*. 2010; 3(1): 91-93.
8. Miller F.M., Laing F.C. Gestational trophoblastic disease <http://brighamrad.harvard.edu/cases/bwh/hcache/34/full.html>
9. Mackenzie F., Mathers A., Kennedy, J. Invasive hydatidiform mole presenting as an acute primary haemoperitoneum. *Br J Obstet Gynecol*. 1993; 100: 953-54.
10. Wilson R.B., Hunter I.S., Dockerty MB. Chorioadenoma Destruens. *Am J Obstet Gynecol*. 1961; 81: 546-59.
11. Hol K., Junnare K., Shekhawat G.S., Damle H. Case of Invasive Mole with Uterine Rupture Presenting as a Hemoperitoneum. *Global Research Analysis*, 2013 Dec; 2(12): 195-96.
12. Branka N., Jelena L. Invasive mole case report of massive uterine destruction- *Med Arh*. 2008; 62: 242-243.
13. Mitani Y., Jimi S., Takao N. Partial resection of the uterus for chorioadenoma destruens. *J Jpn Obstet Gynecol Soc*. 1968 Jul; 15(3): 163-7.
14. Goldstein D.P. and Berkowitz R.S. *Gestational Trophoblastic Neoplasia*. WB Saunders, Philadelphia; 1982. 98-121.