

## Osseous Metaplasia of Peritoneal Deposits in a Case of High Grade Serous Ovarian Carcinoma: An Unusual Presentation

Richa Garg<sup>1</sup>, Suday Halder<sup>2</sup>, Rajesh Kumari<sup>3</sup>, Jyoti Meena<sup>4</sup>

### How to cite this article:

Richa Garg, Suday Halder, Rajesh Kumari *et al.*, Osseous Metaplasia of Peritoneal Deposits in a Case of High Grade Serous Ovarian Carcinoma: An Unusual Presentation. Indian J Obstet Gynecol. 2024;12(4):181-183.

### Abstract

A 60-year-old, postmenopausal woman presented with lower abdominal heaviness in to our OPD. On subsequent examination 7x8cm firm mass was felt through left fornix. CA-125 was found to be 447U/ml, and her CECT was suggestive of 7.7X5.3X6.9CM solid cystic left adnexal mass. Patient underwent Primary cytoreductive surgery. Intraoperatively Left adnexal mass was present measuring 10x8cm, multiple calcified stony hard irregular shaped deposits were present in omentum and paracolic region. Final histopathology report was suggestive of high grade serous ovarian carcinoma pT3cpN0 and calcified deposits were reported as mature cartilaginous tissue. Patient subsequently received 6 cycles of adjuvant chemotherapy. Currently patient is doing well.

**Keywords:** High-grade serous ovarian carcinoma, Primary cytoreductive surgery, Calcified deposits, Mature cartilaginous tissue.

## INTRODUCTION

### Background

Peritoneal calcification occurs in many diseases. In case of ovarian cancer, calcifications are encountered quite rarely, and typically they involve the change itself, which is used to determine the stage of the disease. Ovarian cancer can also cause calcification of distant soft tissues, however the form of calcium deposit in each case of the disease is different. Linear calcifications may

indicate a benign nature of the disease, while strong and massive calcifications of soft tissues already suggest a more malignant process. In the literature, there have been reported cases of calcification in the abdominal wall, which were created as a result of a previous abdominal surgery or trauma. But till now there are two case reports depicting osseous metaplasia in high grade serous ovarian carcinoma. Computed tomography is a highly sensitive tool for the diagnosis of calcifications but its main limitation is low sensitivity for detection of small tumour implants.

**Author's Affiliation:** <sup>1,2</sup>Senior Resident, <sup>3,4</sup>Additional Professor, Department of Obstetrics Gynecology, All India Institute of Medical Sciences, New Delhi 110029, India.

**Corresponding Author:** Rajesh Kumari, Additional Professor, Department of Obstetrics Gynecology, All India Institute of Medical Sciences, New Delhi 110029, India.

**E-mail:** [drrajeshkumari@yahoo.com](mailto:drrajeshkumari@yahoo.com)

**Received on:** 22.10.2024

**Accepted on:** 20.02.2025



## CASE SUMMARY

A 60-year-old, postmenopausal woman, P3L3, presented with lower abdominal heaviness and difficulty in micturition in may 2024 to our OPD. On subsequent examination there was no significant findings in per abdominal and per speculum examination. In per vaginal examination 7x8cm firm, non-tender mass was palpable with restricted mobility in left fornix and in per rectal examination rectal mucosa was free, no POD nodularity was present. CA-125 was found to be 447U/ml, and her CECT was suggestive of 7.7X5.3X6.9 cm left adnexal mass abutting left external and internal iliac vessel and sigmoid superiorly with no e/o infiltration, omental caking was present. Right paracolic peritoneal deposit of 3x2cm was present.

Patient underwent Primary cytoreductive surgery which included Laparotomy followed by peritoneal fluid cytology followed by Total abdominal hysterectomy followed by Bilateral salpingoophorectomy followed by Total omentectomy followed by Excision of enlarged bilateral pelvic lymph nodes followed by Right paracolic peritoneal deposit excision followed by right pelvic peritoneal deposit excision.

Intraoperatively there was minimal ascites. Left adnexal mass was 10x8cm, hard in consistency, whitish yellow in colour, multiple necrosed area, adhered to rectosigmoid and also adhered to uterus, capsule was intact, no surface deposits were present. Right tube and ovary where atrophic omental cake was present in around 6cm length, adhered to sigmoid colon but not infiltrating colon. Rest of the omentum was grossly thickened. Multiple calcified stony hard irregular shaped deposits in omentum- largest 4x5cm. Right paracolic peritoneal white calcified confluent nodular deposit of size 3x2cm was present.

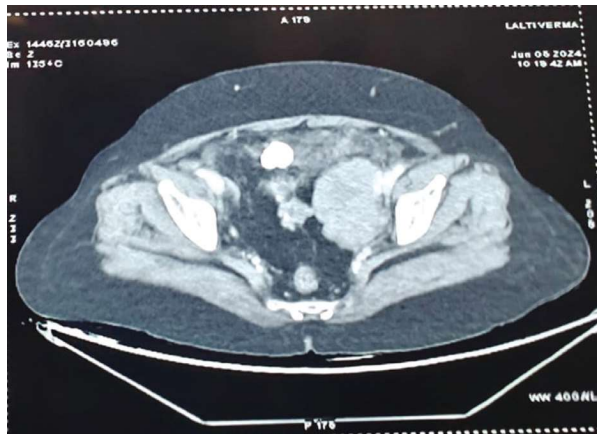
Right pelvic peritoneal deposit of size 2x1 cm was present. Bilateral 2-3 enlarged pelvic lymph nodes were present of largest 2cm size. There was 1000ml blood loss. PCI score was 10/39 and surgical complexity score was 3 It was CC-0 resection. Patient was discharged on POD-3 in stable condition.

Final histopathology report was suggestive of Grossly 9x4x2.5cm left ovarian mass, of high-grade serous histology, positive for WT1, PAX8 and P53 Mutant.

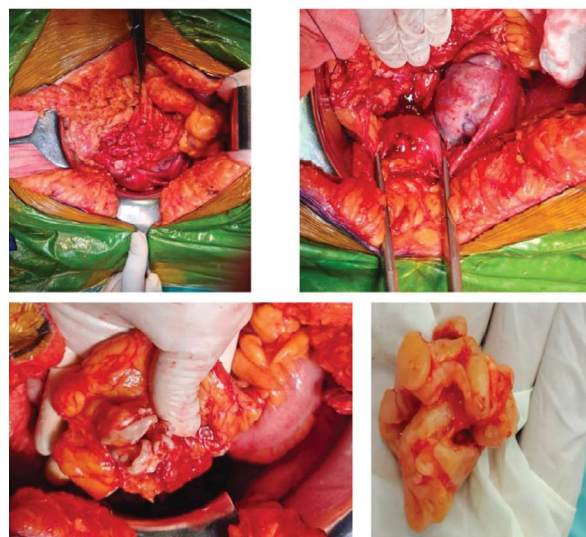Right ovary was free of tumor. Tumor deposit were present on omentum, paracolic deposit, right pelvic peritoneal deposit, largest measuring 2.5cm with staging reported as pT3CpN0. These calcified

deposits were reported as mature cartilaginous tissue.

Patient subsequently received 6 cycles of adjuvant chemotherapy and currently she is doing well.



Preoperative CECT imaging shoeing left adnexal mass of solid cystic consistency and calcified deposit.



Intraoperative images

## DISCUSSION

The cause of ossification of the ovary is not known, though several hypotheses have been suggested. Heterotopic bone formation may be stimulated by blood clots, infections, or traumatic inflammation. Overgrowth of coexisting coalesced psammomatous calcifications or spontaneous necrosis of the tips of papillae of papillary tumors are also possible explanations. Some authors have suggested that metaplastic processes of multipotential stromal cells in neoplastic lesions may result in bone formation and postulated that a tumor may produce bone forming factors like

transforming growth factor (TGF)  $\beta$  and bone morphogenetic proteins (BMP) that cause the metaplastic transformation of undifferentiated mesenchymal stromal stem cells into osteoblasts.<sup>1</sup> Till date there are two case reports depicting osseous metaplasia in high grade serous ovarian carcinoma.<sup>2-3</sup> The most common type of ovarian tumor containing osseous elements is a teratoma. More research is warranted in histogenesis in ovarian carcinoma.

## CONCLUSION

In such type of tumor, aggressiveness is determined by the carcinoma grade stage and pathology and not the benign osseous component. No conclusion can be made regarding the prognostic significance of the presence of bone in an ovarian serous carcinoma due to limited number of reported cases. Therefore, further studies are required to improve understanding of the pathophysiology of this rare phenomenon in ovarian carcinoma.

## REFERENCES

1. Gabrilovich S, Kowal N, Zhang R, Lespinasse P and Heler D. Ovarian endometrioma with osseous metaplasia: a case report and review of the literature. *J Gynecol Surg* 2019; 35: 246- 52.
2. Bosscher J, Barnhill D, O'Connor D, Doering D, Nash J and Park R. Osseous metaplasia in ovarian papillary serous cystadenocarcinoma. *Gynecol Oncol* 1990; 39: 228-31.
3. Barua R and Cox LW. Occurrence of bone in serous cystadenocarcinoma of the ovary. *Aust N Z J Obstet Gynaecol* 1982; 22: 183-6.
4. Catteau X, Preat F, D'haene N, Noël J-C. Osseous metaplasia in low-grade ovarian serous carcinoma with a BRAF mutation: a case report. *Int J Gynecol Pathol*. 2020;40(5):448-51.
5. Misselevich I, Boss JH. Metaplastic bone in a mucinous cystadenoma of the ovary. *Pathol Res Pract* 2000;196:847-8. [DOI] [PubMed] [Google Scholar]